Calcific tendonitis – Iontophorisis and Sonophoresis

It all started with a literature search, looking for ways to better deal with calcifications within muscles and tendons. I came across an article, the before and after x-rays were stark. Eureka! After a lot more research, I came to the conclusion that iontophoresis was a credible approach – but I needed to gain pragmatic insight. An email to an eminent researcher in the field later, tickets booked, bag packed and off I went to Spain!

Dr Marcos E Fernandez-Cuadros MD MSc PhD, a consultant in rehabilitative medicine; is a gentleman and scholar with a deep passion and insight into a discipline of medicine we do not as such have in England. The closest we come is sports medicine – but that does little justice to the 'tools' the rehabilitative specialists in Spain possess and the remit of their practice. It really has to be seen to be believed.

I was warmly welcomed in two hospitals in Spain over two days. In this time I was permitted to shadow treatments, ask questions and formally taught the technique. I was shown research findings for patients with calcific tendons and most generously Dr Marcos took time out of his busy clinic schedule to give me a presentation on calcifications. The presentation I have uploaded to my website www.townosteo.com/research.

Picture 1. Pre-treatment. Note the supraspinatusCalcification.

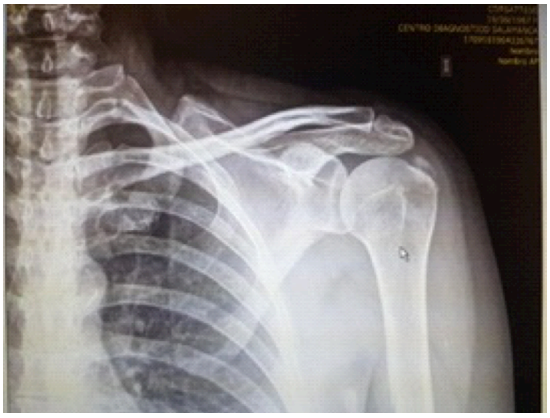

Picture 2. Dr Cuadros's team administered 10 sessions of Iontophoresis and sonophoresis. Complete resorption on plain film x-ray.

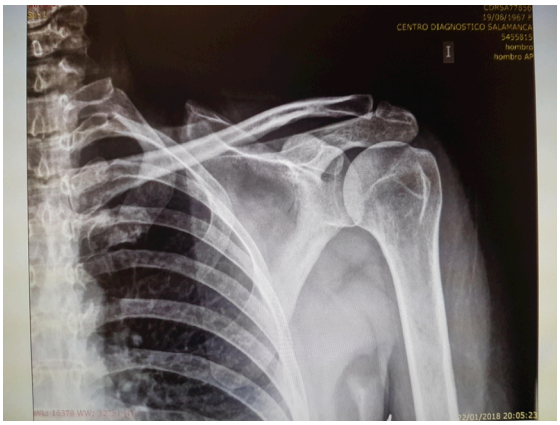

The below is a summary of the work by Dr Marcos E.Fernandez-Cuadros taken with his permission from his book 'Calcifying tendonitis: effect of Physical Therapy and Iontophoresis'.

What is calcific tendonitis?

Calcifying tendonitis (CT) is the intratendinous deposit of calcium apatite within previously healthy tendons and tendon sheaths[1]. Tendons that are particularly vulnerable are shoulder, ankle, knee, elbow, hip, and wrist[2]. Within the shoulder it occurs between 2.7 and 20% in asymptomatic

patients, with an average age between 30 and 50 years, effecting women more than men[3,4] and in 40-54% of patients it is the cause of painful shoulder symptoms[5,6,7].
The pathogenesis is unknown. One theory is that it is precipitated by tendon fibrosis and necrosis, the degeneration of which favouring crystal deposition [8,9]. Other authors believe it is a cell-mediated process. [4,9,10]

Three stages with clinical, histological and radiographic correlation are described.

1) Pre-calcification. Tenocyte metaplasia and chondrocyte transformation.
2) Calcification a) formative (reservoir of vesicles in matrix), b) Resorptive phase (spontaneous resorption during phagocytosis by macrophages)
3) Post-calcification (with restitution of the tendon architecture). [11]

The clinical picture is highly variable. Patients can present with chronic pain, acute pain crises (mainly associated with the resorptive phase) and asymptomatic patients. [12] CT is more common in asymptomatic patients. [13]

Conclusion

Treatment of CT is initially conservative and depends on its evolution.[14] Options include therapeutic abstention in asymptomatic patients; NSAIDs, physiotherapy [15], electrotherapies (micro waves, short waves. TENS, ultrasound, interferential, pulsed electromagnetic therapy, sonophoresis, iontophoresis), shock-wave therapy [16] and finally surgical approaches [17,18]. Shockwave and arthroscopy are advanced therapeutic options [19] that are as effective as iontophoresis, however, they are painful, expensive and not exempt from risks of complications. [20] Shock wave is further limited, current guidelines prohibit peri-spinal use, although research is innovatively showing otherwise. [21]
Iontophoresis with 5% Acetic Acid and ultrasound (sonophoresis) is a safe, simple and inexpensive technique capable of reducing pain and calcification within the shoulder, elbow, wrist, hip, knee and ankle. [1]

For further details on what Iontophoresis & Sonophoresis is, the evidence base and methodology, please do consider ordering the book
Name: Calcifying Tendonitis: effect of Physical Therapy and Iontophoresis
Author: Marcos E. Fernández-Cuadros
ISBN: 978-3-330-03370-2

Yasin Tayebjee

References

1 M.E.F. Cuadros, O.S.P. Moro, F.D. Ramos, M.J.A. Florin. Acetic Acid Iontophoresis and Ultrasound effectiveness on Calcifying Tendonitis of the Shoulder, Elbow, Wrist, Hip, Knee and Ankle: A Non randomized multicenter control trial. Ortho & Rheum Open Access. 2016;3(3):1-7

2 J.D. Rees, A.M. Wilson, R.L. Wolman . Current concepts in the management of tendon disorders. Rheumatology. 2006. 45(5):508-521

3 Porcellini G, Paladini P, Campi F, Paganelli M. Arthroscopic treatment of calcifying tendinitis of the shoulder: Clinical and ultrasonographic follow-up findings at two to five years. J Shoulder Elbow Surg. 2004;13:5003-8

4 H.K. Uhthoff, G.F. Dervin, J.F. Loehr. Tendinitis calcificante. The shoulder, 3rd Ed. Rockwood C Jr, Matsen FA III, Wirt MA, Lippitt, Tomo II. Madrid: Marban 1033-1057:2006

5 K.M.Olsen & F.S. Chew. Tumoral calcinosis: Perls, polemics, and alternative possibilities 1. Radiographics. 2006. 26(3):871-885

6 D.J. Flemmings, M.D. Murphey, K.M. Shekitka, H.T. Temple, J.J. Jelinek, M.J. Kransdorf. Osseous involvement in calcific tendinitis: a retrospective review of 50 cases. American Journal of Roentgenology. 2003. 181(4):965-72

7 C Krasny, M Enenkel, N Aidner, M Wlk, F Landsiedl. Ultrasound-guided needling combined with shock-wave therapy for the treatment of calcifying tendonitis of the shoulder. Bone & Joint Journal. 2005. 87(4):501-07

8 L.H. McLaughlin. Lesions of the musculotendinous cuff of the shoulder. III Observations on the pathology, course and treatment of calcific deposits. Annals of Surgery. 1946. 124(2),354

9 F.J.J. García, C.G. Movilla a, A.C. López. Effectiveness of extracorporeal shock wave therapy in calcific tendonitis of the shoulder. Rev Esp Reumatol. 2004;31:116-21

10 H.K. Uhthoff. Calcifying tenditinis, an active cell-mediated calcification. Virchows Archiv A. 1975; 366(1),51-58

11 M.E.F. Cuadros, O.S.P Moro, S.Á. Rabasa, J.G. González, J.A.M Canelo. Calcifying Tendonitis of the Shoulder: Risk Factors and Effectivenessof Acetic Acid Iontophoresis and Ultrasound. Middle East J Rehabil Health. 2016;3(4):e41112

12 J.L. Barrera-Cadenas, A Campa-Rodriguez, V Vallina Garcia-Prendes. Resultados del tratamiento artoscopico de las tendinitis calcificantes del manguito de los rotatodores del hombre. Rev. esp. cir. Ortop. Traumatol. 2010;54(2):100-105

13 J.G. Llorente, G.E. Aguirregoikoa, M.L. G Vivar, & J.M.A. Albizuri. Protocolo diagnóstico del hombro doloroso crónico. Medicine - Programa de Formación Médica Continuada Acreditado.2009; 10(33),2222-5

14 M.E. F. Cuadros, O.S.P. Moro, J.N. Blasco, V.R. García, A.O. Pardeiro, J.A.M.Canelo. Calcifying Tendonitis of the Shoulder: Risk Factors and Effectiveness of Physical Therapy. Occupational Medicine & Health Affairs. 2015;3(220), 2

15 J Hamada, W Ono, K Tamai, K Saotome, T Hoshino. Analysis of calcium deposits in calcific periarthritis. J Rheumatol. 2001; 28:809-13

16 M Loew, W Jurgowski, HC Mau, M Thomsen. Treatment of calcifying tendonitis of rotator cuff by extracorporeal shock waves: A preliminary report. J Shoulder Elbow Surg. 1995;4:101-5

17 A.J. Martín, F.J.S. Yubero, M.Z. Carmona, F.J.N. Cid, F.J.C. Asensi , S.P. Hidalgo. Arthroscopic treatment of calcific tendinitis of the shoulder. Trauma Fund MAPFRE. 2012;23(supple 1:5):32-37

18 C.S, Neer II. Shoulder reconstruction. Philadelphia: Saunders; 1990. P.427-3

19 P. Ogon, N.P. Suedkamp, M Jaeger, K. Izadpanah, W. Koestler, D. Maier. Prognostic factors in nonoperative therapy for chronic symptomatic calcific tendinitis of the shoulder. Arthritis & Rheumatism. 2009;60(10):2978-84

20 E.C. Alvarez. Prospective study comparing the results obtained with three electrotherapy treatments in calcified tendinopathies of the supraspinatus. Tesis Doctoral. Valladolid. 2015

21 T.Y. Lin, J.T. Chen, Y.Y. Chen, T.W. Chen, C.L. Lee, C.H. Chen, M.H. Huang. The efficacy of ultrasound-guided extracorporeal shockwave therapy in patients with cervical spondylosis and nuchal ligament calcification. Kaohsiung J Med Sci. 2015;31(7):337-43